



PATIENT

Margarita Muldoon

SPECIES

Canine

BREED

Pomeranian Mix

SEX

Female Spayed

AGE

13 years

WEIGHT

15.2lbs

PRESENTING CLINICAL SIGNS

History: Immune - mediated thrombocytopenia. Grade III/VI heart murmur. Arthritis in both stifles. L medial patella luxation. Mild dental disease. BP: 224, 246, 215mmHg.

ECHOCARDIOGRAM FINDINGS

2D, m-mode, color flow and Doppler imaging is available.

Left ventricle: The LV diameter is normal with adequate myocardial function. LV wall thicknesses are normal.

Left atrium: The left atrium is mildly dilated.

Mitral valve: The mitral valve is diffusely thickened with mild prolapse into the left atrial lumen. Moderate eccentric mitral regurgitation with a normal velocity.

Aortic valve/aorta: The aortic valve is normal in morphology and mobility. Normal aortic outflow velocity; laminar flow. Mild aortic insufficiency.

Right ventricle: Normal right ventricular diameter and morphology indicating no overt evidence of pulmonary arterial hypertension.

Right atrium: Normal RA dimension.

Tricuspid valve: The tricuspid valve appears mildly thickened with moderate tricuspid regurgitation; normal velocity.

Pulmonic valve/pulmonary artery: The pulmonic valve is normal in morphology and mobility. No pulmonic insufficiency. Normal RVOT velocity; laminar flow.

Pericardium/other: No pericardial or pleural effusion noted. No obvious cardiac masses.

Heart rhythm: ECG reveals a sinus rhythm with an average HR of 120bpm.

INTERPRETED BY

Maggie Machen
 Lamy, DVM
 DACVIM (Cardiology)

2-Dimensional Measurements

Ao diam (cm)	1.6
LA diam (cm)	2.2
LA:Ao (Swe)	1.4
IVS thickness (cm)	0.6
LVID diastole (cm)	3.1
PW thickness (cm)	0.5
LVID systole (cm)	1.4
FS (%)	56

Doppler Measurements

PV Vmax (m/s)	0.7
AoV Vmax (m/s)	1.4
MR Vmax (m/s)	6.0
TR Vmax (m/s)	2.6
TR PG (mmHg)	27

IMAGING

PERFORMED BY

Eduardo Rodriguez
 III, RCS

INTERPRETATION OF THE FINDINGS

The cause of the murmur is chronic degenerative valve disease causing moderate mitral and tricuspid regurgitation. Lack of significant left atrial enlargement indicates the current risk for complication is low. A small aortic valve insufficiency is noted, and reassessing BP is recommended as below. No concurrent issues such as systolic dysfunction or pulmonary hypertension are noted in this study. Assessment of progression in the future will help predict long term prognosis, which is highly variable at this stage (B1).

HOSPITAL NAME

Littleton Animal
 Hospital

REFERRING VET

Dr. Kalani

The reported blood pressure is elevated, and should be reassessed for accuracy/persistence particularly given no reported clinical signs of severe hypertension (retinal changes, etc) or evidence of LVH on echo. Ideally obtain serial measurements in a controlled, low stress environment and continue until 3 consecutive readings plateau within 5mmHg of variability. If persistently >180mmHg despite a relatively calm demeanor, recommend institution of amlodipine to effect. Additionally if deemed accurate, screening for predisposing underlying causes of SHT is recommended (Cushings,

INVOICE

31849

DATE

7/14/23



PATIENT
 Margarita Muldoon

PLN, adrenal tumor, etc), as primary disease is relatively uncommon and a rule out diagnosis.

SPECIES
 Canine

RECOMMENDATIONS

- In an asymptomatic dog without significant left atrial enlargement, no cardiac medications are clearly indicated.
- Reassess BP as discussed.
- Omega fatty acid supplementation and mild salt restriction may be of some long-term benefit.
- Anesthetic risk is considered mild if needed. Cardiac protective drug choices (opioid/benzodiazepine premedication, propofol or alfaxalone induction, isoflurane gas) are recommended. Pre-oxygenate for 5-10 minutes prior to induction. Monitor for arrhythmias, hypotension, and hypoxia both intra and post-operatively and intervene as necessary. Mild IV fluid restriction is recommended to avoid fluid overload. Avoid heart rate stimulating drugs such as atropine unless clinically indicated.
- Monitor for development of a cough, labored breathing, exercise intolerance or collapse episodes.

BREED
 Pomeranian Mix

SEX
 Female Spayed

AGE
 13 years

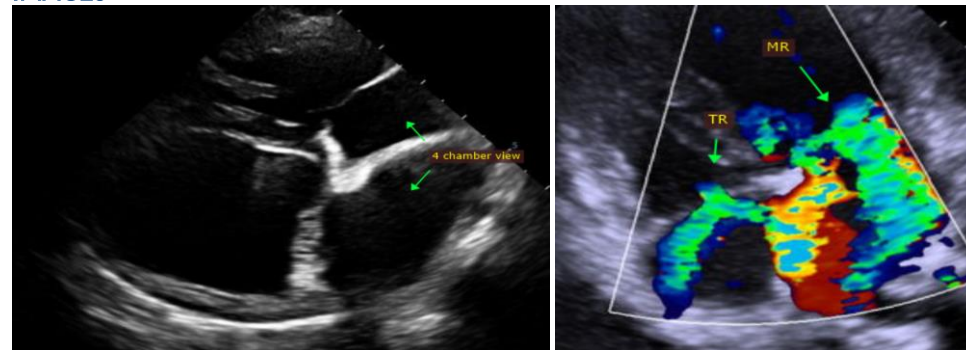
WEIGHT
 15.2lbs

PLAN

- Recommend conservative monitoring with a recheck echocardiogram in 6 months, sooner if any development of clinical signs.

INTERPRETED BY
 Maggie Machen
 Lamy, DVM
 DACVIM (Cardiology)

IMAGES



IMAGING PERFORMED BY
 Eduardo Rodriguez
 III, RCS

HOSPITAL NAME
 Littleton Animal
 Hospital

The information and recommendations provided are based on the images presented by the referring veterinarian. No evaluation can be communicated regarding pathology that was not visible in the image/video clips provided.

REFERRING VET
 Dr. Kalani

Thank you for this referral. This report was generated using transcription software, and minor dictation errors may be present. If the clinical or image interpretation does not parallel your findings or if I can be of any further assistance, please contact me.

INVOICE
 31849

Maggie Machen Lamy, DVM
 Diplomat of the American College of Veterinary Internal Medicine (Cardiology)
 info@sonopath.com

DATE
 7/14/23

Echocardiogram performed by: Eduardo Rodriguez III, RCS
 Pet Animal Ultrasound Service (4paus.com)